

40



**MASINDE MULIRO UNIVERSITY OF
SCIENCE AND TECHNOLOGY
(MMUST)**

MAIN CAMPUS

**UNIVERSITY EXAMINATIONS
2021/2022 ACADEMIC YEAR**

**MAIN EXAM
THIRD YEAR SECOND TRISEMESTER**

**FOR THE DEGREE
OF
BACHELOR OF OPTOMETRY**

COURSE CODE: BOV 320

COURSE TITLE: Clinical optometric procedures IV PRE-CLINIC
ROTATIONS

DATE: 25/04/2022

TIME: 3-5PM

INSTRUCTIONS

Answer all questions (100 MARKS)

TIME: 3 Hours

MMUST observes ZERO tolerance to examination cheating



1.A) Discuss the Invasive Tear Break-up time under the following headings:

- i)Function 2mks
- ii)Procedures 7mks.
- iii).Interpretation of findings 6mks.
- B).Briefly discuss the Schirmer test 5mks.

2A).Discuss the types of pressure patch 2mks.

B).Outline the removal of pressure patch when due for removal 8mks.

3A).Explain five components that are included in case history taking for a patient with foreign body 5mks.

B).Briefly discuss the following words as used in corneal foreign body descriptions: 10mks

- i).Superficial Vs Deep
- ii).Organic Vs Inorganic
- iii).Penetrating Vs Perforating
- iv).Associated Uveitis
- v).Intraocular foreign body

C).Briefly describe how the following foreign body removal instruments are used: 10mks.

- i)Bailey nylon loop
- ii)Golf club spud
- iii) Jeweller's forceps
- iv)Battery powered drill
- v)Alger brush

4).The Visual Acuity of the patient is HM(hand movement) both eyes.When given +0.25DSphere,vision improves to 6/6 both eyes.

A)What is the likely diagnosis of the patient? And why? 2mks.

B)What are some other tests that can be used to diagnose the above condition? 3mks.

5).A patient comes to your optometric clinic and on examination he/she has a poor visual acuity.On doing refraction,the VA (visual Acuity) does not improve with the correction.

A).Identify any five tests that you would employ to probe further or investigate the patient's condition 5mks.

Bi).What is Carotid Artery Auscultation?

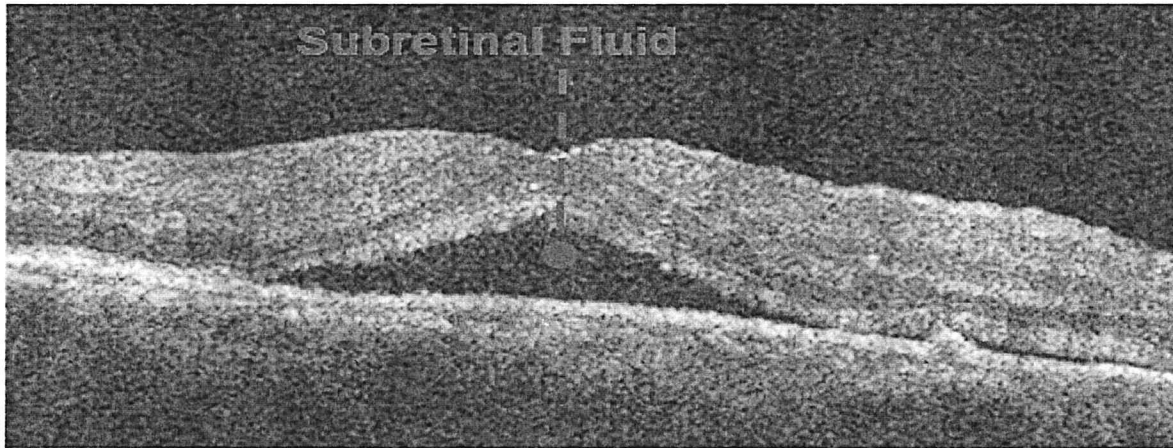
2mks.

ii).What is a Carotid Bruit in relation to Carotid Artery auscultation? 1mk.

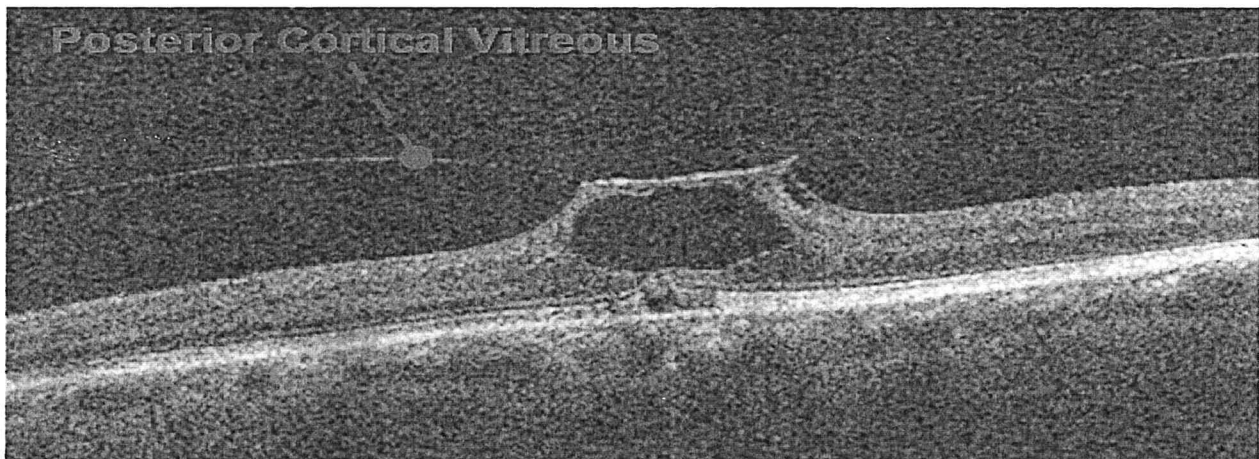
iii).Identify and briefly describe three possible results from Carotid Auscultation 3mks.

iv).What is Orbital Auscultation? Highlight any three patient presentations that may prompt an optometrist to perform Orbital Auscultation. 4mks.

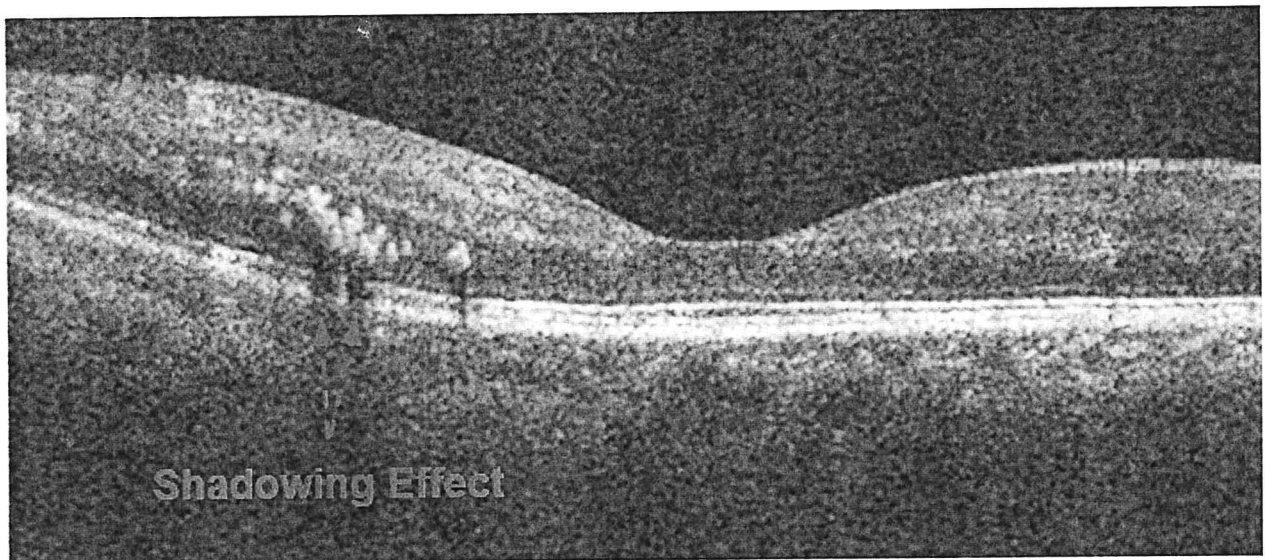
6). Describe the images below (3marks)



a).



b).



(c).

(d). Discuss the basic anatomical and physiological principle used in interpretation of Fluorescein Angiography (FA) 4marks.

(e). Describe the step followed during analysis of X-ray results 3marks.

7a). What is a bandage soft contact lens? 2mks.

b). Tabulate the advantages and the disadvantages of bandage soft contact lens 8mks

8a). Name the hyperelective and hyporelective layers in an OCT Scan 3mks.

b). What principle does the OCT use? 2mks.